

Fatal Ecstasy-induced malignant hyperthermia with rhabdomyolysis. A case report

Juliane Lang^{1,*}, Reinhard Dettmeyer¹, Veronique Henn², Christoph G. Birngruber¹, Florian Veit¹

Abstract: There is an increasing number of reports concerning lethal courses following consumption of 3,4-Methylenedioxymethamphetamine (MDMA), namely Ecstasy. Autopsy findings in cases of MDMA intoxications are described, however Ecstasy-associated pathological findings should be separated from Ecstasy-induced findings. This case report presents typical Ecstasy-induced findings due to an obviously genetic disposition leading to malignant hyperthermia and severe rhabdomyolysis. Medicolegal aspects are relevant because there is a therapeutic option to save life by injecting Dantrolene® when first symptoms are recognized.

Key Words: Ecstasy, 3,4-Methylenedioxymethamphetamine (MDMA), malignant hyperthermia, rhabdomyolysis.

Ecstasy is the common name for 3,4-Methylenedioxymethamphetamine (MDMA). Over the last years, the number of reports on adverse somatic effects of Ecstasy has increased, including disturbances of the thermoregulation and severe courses with fulminant hepatic failure leading to death [1-6]. The range of effects includes acute and chronic liver disease, liver failure, malignant hyperthermia, coagulation disorders causing thrombotic and/or haemorrhagic complications in various organs. Additionally, rhabdomyolysis, acute renal failure, arrhythmia and sudden cardiac death are reported as well as disturbances in the water and electrolyte balance, aplastic anaemia and severe arterial hypertension [7-11]. Malignant hyperthermia is a well-known complication during anaesthesia [12]. This complication can also be found in cases of MDMA-intoxication, especially if there is a genetic disposition [13, 14]. Like in cases of hyperthermia during anaesthesia, which can be triggered by a variety of substances, the immediate administration of Dantrolene®

seems to be the one and only therapeutic option to avoid a lethal course [15-20]. We report about a young woman who consumed MDMA and developed hyperthermia, delirious behaviour and rhabdomyolysis leading to death.

CASE REPORT

A 37-year-old woman was found naked and lifeless on the floor of her bedroom. Hours before her boyfriend offered her MDMA, and under the influence of alcohol the woman consumed an unknown number of pills. After that, she shut the door of her room, developed a delirious behaviour and, as her boyfriend reported later, she started sweating, got undressed and threw herself on the ground causing visible hematoma (Fig. 1). The boyfriend, who had consumed drugs as well, looked through the window and saw her body lying lifeless on the ground of her room. Although he called the emergency, resuscitation failed and the police was informed. About three hours after death, the rectal temperature was 41.7°C.

1) Institute of Forensic Medicine, Justus-Liebig University Giessen, Germany

* Corresponding author: Institute of Forensic Medicine, Frankfurter Str. 58, 35392, Gießen, Germany, Tel.: +49641 9941421, Fax: +49641 9941419, Email: Juliane.Lang@forens.med.uni-giessen.de

2) Institute of Pathology, Klinikum Lüdenscheid, Germany

Autopsy

Autopsy revealed well demarked fresh hematoma. Partially, the skeletal muscles were of grey-red colour, pale and softened. Acute congestion and oedema of all internal organs were found. Brain weight: 1373 g, left lung: 633 g, right lung: 766 g. Macroscopically all other findings were according to the age of the woman. There was no coagulated blood in the large vessels.

Toxicology

Toxicological investigations showed the following substances and concentrations in femoral blood (Table 1).

Femoral blood concentrations of MDMA above 600 µg/L can be considered comatose-fatal [21].

Analysis of different sections along the hair revealed Diazepam (35-170 ng/mg), MDA (0.25-0.59 ng/mg), MDMA (13-23 ng/mg), Nordazepam (0.08-0.13 ng/mg), Temazepam (0.01-0.12 ng/mg) and Lorazepam

Table 1. Toxicological investigations of femoral blood

MDA	72 µg/L
MDMA	4200 µg/L
Diazepam	28 µg/L
Blood alcohol concentration (BAC)	0,49 ‰

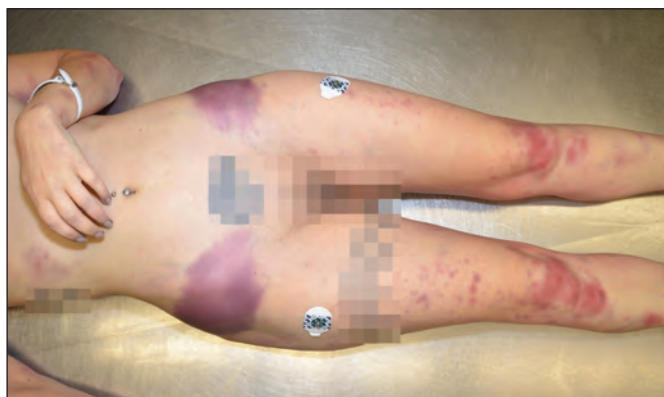

Figure 1. Hematoma caused by self-throwing on the ground as part of delirious behavior.

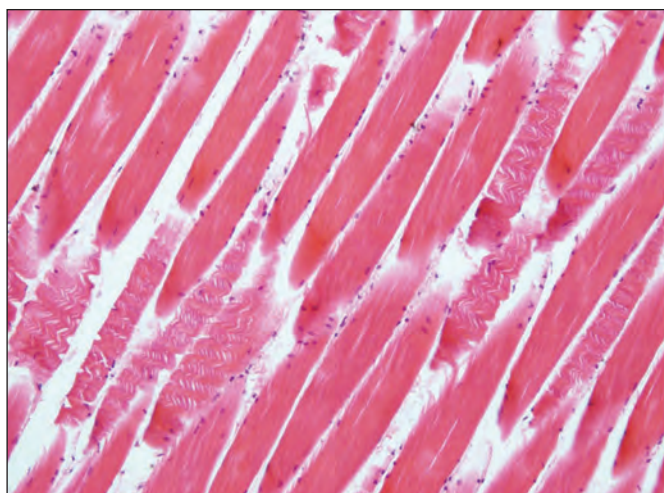


Figure 2. Severe rhabdomyolysis found in parts of the skeletal muscles (HE x100).

(0.02-0.09 ng/mg) concerning a period of 10 to 12 months prior to death.

Histopathology

In accordance with age, there were non-specific mild histopathological findings, e.g. mild interstitial myocardial fibrosis, lung oedema, brain oedema, mild fatty transformation of hepatocytes with single cell necrosis. Skeletal muscles presented a severe rhabdomyolysis already visible using conventional histological stainings with partial loss of transverse striation (Fig. 2). Immunohistochemistry was able to demonstrate lack of desmin within parts of the muscle fibers (Fig. 3). There were no anti-myoglobin-positive protein deposits in the renal tubuli. Obviously the woman died too short after the intake of MDMA to develop the typical picture with anti-myoglobin-positive proteins inside a lot of renal tubuli accompanied by renal failure. In contrast there were 500 ml urine in the bladder pointing to an intact renal function.

DISCUSSION

In the literature, autopsy findings are presented found in cases of amphetamine consumption including self-harming prior to death and histopathological findings following the autopsy [1, 22]. It might be possible that in cases of long running amphetamine/MDMA consumption the risk of some histopathological changes increases, e.g. coronary sclerosis, interstitial myocardial fibrosis, scars in the myocardium or damages of the liver [1, 4]. Nevertheless, these findings can be regarded as non-specific and might also be caused by other drugs or diseases (e.g. consumption of cocaine or pre-existing arterial hypertension independent from any drug abuse). Although severe histopathological cardiovascular changes such as myocardial hypertrophy and myocardial interstitial fibrosis can be considered as a result of long-term consumption of e.g. amphetamines/MDMA, such findings may occur for a variety of reasons.

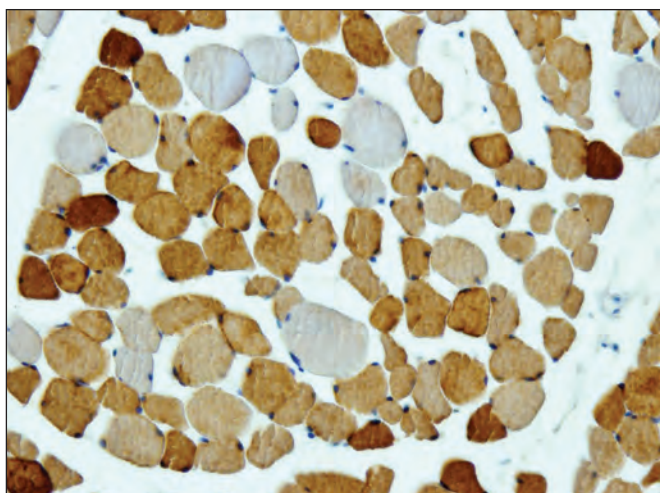


Figure 3. Skeletal muscle fibers with partial loss of desmin due to rhabdomyolysis (x200).

In addition to an acute intoxication with amphetamines/MDMA, previous frequent consumption of drugs over a longer period has to be proven by hair analysis. Most histopathological findings cannot be considered to be the result of amphetamines/MDMA consumption only. Acute amphetamines/MDMA-intoxication is not a necessity for the most histopathological changes which could be the result of a long-term consumption of these or other drugs anyway. So the majority of histopathological findings in cases of acute amphetamine/ecstasy intoxication could be considered to be drug-associated, but not to be specifically drug-induced. On the other hand there are definite findings pointing towards a specific methamphetamine-induced damage in the myocardium [23]. On an individual basis, it seems to be difficult to differentiate between methamphetamine-associated findings and methamphetamine-induced findings, e.g. an inflammatory cardiomyopathy with similar changes must be taken into account.

In contrast to the non-specific findings mentioned above, which may or may not contribute to death under the influence of lower concentrations of amphetamines/MDMA, Ecstasy triggers malignant hyperthermia with rhabdomyolysis, a specific finding and MDMA-induced reaction when there is a genetic predisposition, namely the ryanodine receptor [24-28].

This genetic predisposition increases the risk

of malignant hyperthermia in combination with severe rhabdomyolysis involving all parts of the skeletal muscles. Nevertheless, a comprehensive revision of every case is obligatory: the combination of delirious behaviour, high rectal temperature and rhabdomyolysis as well as each finding itself can point towards an intake of MDMA as the triggering substance. Despite a genetic predisposition, hair analysis in the present case demonstrates that frequent consumption of low doses of MDMA in the previous months does not necessarily lead to hyperthermia and rhabdomyolysis. Since the administration of Dantrolene® is an therapeutic option, persons who are aware of a recent MDMA-consumption, nearby the drug-victim and realizing the typical symptoms (fever, delirious behaviour) have to call the emergency immediately in order to avoid charges by the police and the prosecution [17-20, 29]. Nevertheless, a drug-induced psychotic reaction should be taken into account. Forensic physicians should have in mind that the high rectal temperature will not be found after a longer post-mortem interval. In such cases, only histopathological investigations of skeletal muscles will reveal an MDMA-induced rhabdomyolysis and other histopathological findings described in the literature [30].

Conflict of interest. The authors declare that they have no conflict of interest concerning this article.

References

1. Karch SB. Pathology of drug abuse. 4th ed.. CRC Press, Boca Raton, FL. USA; 2009. p. 282.
2. Henry JA, Jeffreys KJ, Dawling S. Toxicity and deaths from 3,4-methylenedioxyamphetamine ("ecstasy"). *Lancet*. 1992; 340:384-387.
3. Mehan AO, O'Shea E, Elliott JM, Colado MI, Green AR. A neurotoxic dose of 3,4-methylenedioxyamphetamine (MDMA; ecstasy) to rats results in a long-term defect in thermoregulation. *Psychopharmacology*. 2001; 155:413-418.
4. Garbino J, Henry JA, Mentha G, Romand JA. Ecstasy ingestion and fulminant hepatic failure: liver transplantation to be considered as a last therapeutic option. *Vet Hum Toxicol*. 2001; 43:99-102.
5. Gill JR, Hayes JA, De Souza IS, Marker E, Stajic M. Ecstasy (MDMA) deaths in New York City: a case series and review of the literature. *J Forensic Sci*. 2002; 47:121-126.
6. Trauer H, Günzel A, Dreßler J. Methamphetamin-assoziierte Todesfälle bei gerichtlichen Sektionen im Bereich Leipzig/Chemnitz. *Rechtsmedizin*. 2015; 25: 350-351
7. Mas M, Farre M, Torre R de la, Roset PN, Ortuno J, Segura J, Cami J. Cardiovascular and neuroendocrine effects and pharmacokinetics of 3,4-methylenedioxyamphetamine in humans. *J Pharmacol Exp Ther*. 1999; 290:136-145.
8. Nimmo SM, Kennedy BW, Tullett WM, Blyth AS, Dougall JR. Drug-induced hyperthermia. *Anaesthesia*. 1993; 48:892-895.
9. Screaton GR, Singer M, Cairns HS, Thrasher A, Sarnar M, Cohen SL. Hyperpyrexia and rhabdomyolysis after MDMA ("ecstasy") abuse. *Lancet*. 1992; 339:677-678.
10. Ball SP, Johnson KJ. The genetics of malignant hyperthermia. *J Med Genet*. 1993; 30:89-93.
11. Brown C, Osterloh J. Multiple severe complications from recreational ingestion of MDMA ("Ecstasy"). *J Am Med Assoc*. 1987; 258: 780-781.
12. Ellis FR, Halsall PJ, Christian AS. Clinical presentation of suspected malignant hyperthermia during anaesthesia in 402 probands. *Anaesthesia*. 1990; 45:838-841.
13. Dar KJ, McBrien ME. MDMA induced hyperthermia: report of a fatality and review of current therapy. *Intensive Care Med*. 1996; 22: 995-996.
14. De la Torre R, Farre M, Roset PN, Pizarro N, Abanades S, Segura M, Segura J, Cami J. Human pharmacology of MDMA: pharmacokinetics, metabolism and disposition. *Ther Drug Monit*. 2004; 26:137-144.
15. Campkin NJ, Davies UM. Treatment of "ecstasy" overdose with dantrolene. *Anaesthesia*. 1993; 48:82-83.
16. Larner AJ. Dantrolene and "ecstasy" overdose. *Anaesthesia*. 1993; 48:179-180.
17. Singarajah C, Lavies NG. An overdose of ecstasy. A role for dantrolene. *Anaesthesia*. 1992; 47:686-687.
18. Webb C, Williams V. Ecstasy intoxication: appreciation of complications and the role of dantrolene. *Anaesthesia*. 1993; 48:542-543.
19. Barrett PJ. Ecstasy and dantrolene. *BMJ*. 1992; 305:1225.
20. Kolb ME, Horne ML, Martz R. Dantrolene in human malignant hyperthermia: a multicenter study. *Anesthesiology*. 1982; 56:254-262.
21. Baselt RC. Disposition of Toxic Drugs and Chemicals in Man. 9th ed. Rittenhouse Book Distrib. 2011.

22. Jachau K, Knut B. Straftat, Amphetamine, Selbstverletzung. Rechtsmedizin. 2015; 25: 366
23. Karch SB. The unique histology of methamphetamine cardiomyopathy: a case report. Forensic Sci Int. 2011; 212:e1-e4.
24. Fill M, Coronado R, Mickelson JR, Vilven J, Ma JJ, Jacobson BA, Louis CF. Abnormal ryanodine receptor channels in malignant hyperthermia. Biophys J. 1990; 57:471-475.
25. Fletcher JE, Tripolitis L, Hubert M, Vita GM, Levitt RC, Rosenberg H. Genotype and phenotype relationships for mutations in the ryanodine receptor in patients referred for diagnosis of malignant hyperthermia. Br J Anaesth. 1995; 75:307-310.
26. Gillard EF, Otsu K, Fujii J, Khanna VK, de Leon S, Derdemezi J, Britt BA, Duff CL, Worton RG, MacLennan DH. A substitution of cysteine for arginine 614 in the ryanodine receptor is potentially causative of human malignant hyperthermia. Genomics. 1991; 11:751-755.
27. Quane KA, Ording H, Keating KE, Manning BM, Heine R, Bendixen D, Berg K, Krivosic-Horber R, Lehmann-Horn F, Fagerlund T, McCarthy TV. Detection of a novel mutation at amino acid position 614 in the ryanodine receptor in malignant hyperthermia. Br J Anaesth. 1997; 79:332-337.
28. Phillips MS, Khanna VK, De Leon S, Frodis W, Britt BA, MacLennan DH. The substitution of Arg for Gly2433 in the human skeletal muscle ryanodine receptor is associated with malignant hyperthermia. Hum Mol Genet. 1994; 3:2181-2186.
29. Tehan B. Ecstasy and dantrolene. BMJ. 1993; 306:146.
30. Fineschi V, Centini F, Mazzeo E, Turillazzi E. Adam (MDMA) and Eve (MDEA) misuse: an immunohistochemical study on three fatal cases. Forensic Sci Int. 1999; 104: 65-74.