

## Problems of forensic anthropological identification of carbonized human remains<sup>i</sup>

Viorel Panaitescu<sup>1\*</sup>, Mariana Roșu<sup>2</sup>,

---

**Abstract:** The forensic anthropological identification has been performed on carbonized bones found in a burned vehicle. Odontological examination revealed: 2 mandible fragments (right and left) with amalgam fillings on tooth 46 and partial eruption of 38; one maxillary fragment with 28 tooth partially erupted. The other bony fragments couldn't have been used for identification purposes due to the high carbonization degree and to the uncharacteristic morphological features. Serological exam results (blood group 0) has been interpreted as false positive, due to agglutination degradation. Within the process of identification of the person that the fragments belonged to, we established: gender (based on hip bone morphology and presence of male genitalia), possible age (based on the reduced abrasion degree), the correspondence between the odontological examination results and the ante mortem dental records and the DNA prints' correspondence between that extracted from the fragments and those obtained from the missing person's parents.

**Key words:** identification of carbonized human remains; carbonized bones; anthropological and odontological examination; blood group determination; correspondence between the features of the teeth found on the carbonized bones and those in the dental records; DNA analysis

### History of the case

On September, 26<sup>th</sup>, 2002, in a valley, by a roadside, the metal structure of a completely burned car has been found. On the seats' metal skeleton, there has been found a carbonized body. By the pedals, there have been found bones' fragments. Foregoing investigations have shown that the car belonged to a male person, 29 years old, called E.D.

The material that is object of the expertise consists of five fragments, dispersed bony fragments, teeth, clothes pieces (fragments of jeans). All these are very friable, as effect of the prolonged exposure to high temperature.

---

1\*) Corresponding author, M.D., Prof., Head of Identification Department, National Institute of Legal Medicine "Mina Minovici", Bucharest – 9, Șos. Vitan Bârzești, 4th district, 042122, Bucharest, Romania; tel +40-2133-21217 / int. 139.

2) M. D., Identification Department, National Institute of Legal Medicine "Mina Minovici", Bucharest

Police presented us a complete report, including pictures and movies recorded on the scene and provided significant data on the missing person, that have been of real help in order to proceed to identification work:

- Blood group of the missing person was previously known as O.
- Dental records, covering the examinations and treatments done during the last few years. According to those records, teeth 28 and 38 should have been partially erupted and two amalgam fillings should have been found on 46 tooth.

Police requested a forensic anthropological expertise on the human remains, that should answer the following questions:

#### Goals of the expertise:

- Are the remains human or not?
- What are the approximate age and the gender of the body?
- Can the remains belong to the 29 years old male person called E.D.?
- Which is the cause of death?
- Can there be identified any lesions caused by a car accident? If so, are they related to the cause of death?
- Are there any other trauma signs that can explain the cause of death?

#### **Anthropological and odontological examination**

Examination has been performed on the following pieces that included bony pieces, teeth and soft tissues, all with significant alteration induced by exposure to fire:

#### **A. Fragments of the upper part of the body:**

*The skull base and the facial bones* are showing the following findings

- Skull vault is missing, while the edges of the remaining skull base are irregular
- Facial bones are carbonized, black, and very fragile.
- In the orbital holes there are black, fragile remains of the eye globes.
- Orbits are rectangular shaped, with rounded edges; width of left orbit is 4.7cm.
- The palatine vault is extremely deep.

*The structures of the oral cavity* found among the skeletal remains consist of:

- A fragment of the right half of the mandible, with tooth 46 present, having two amalgam fillings – on vestibular (photo1) and occlusal (photo 2) faces.
- A fragment of the left half of the mandible, with tooth 38 partially erupted.
- Maxilla, partially carbonized, with tooth 28 partially erupted. Some teeth were present, with reduced abrasion degree and with multiple alterations due to the prolonged exposure to fire and high temperature: fissures on the crowns, one radicular fracture.
- Some teeth are missing – 11, with the corresponding socket empty and having sharp edges (indicators of a post mortem dental loss); sockets of the other missing teeth (16, 18) are closed, filled with bony structures (indicating old ante mortem dental losses).
- The tongue is carbonized and covered with ashes.
- Both mandible fragments showed an intense degree of bone carbonization.

- Detached teeth have also been found: 2 premolars, one molar, 2 canines – one of them with a root fragment missing, the other with a crown fragment missing and 2 incisors.

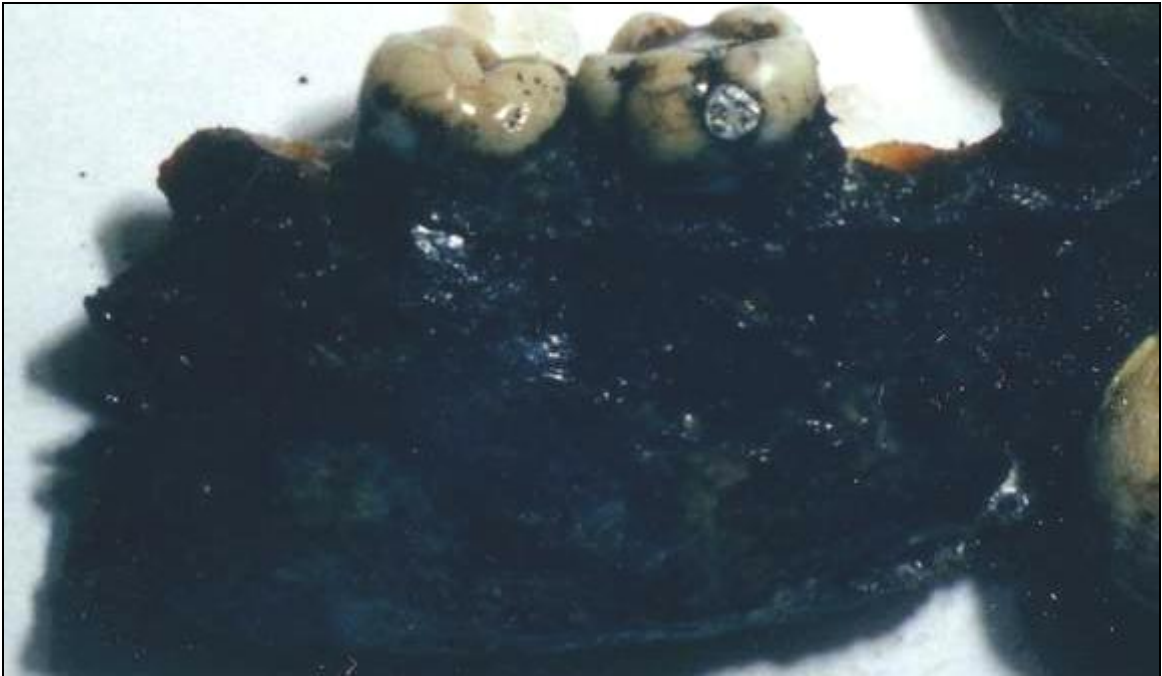

Photo 1 – right mandible fragment, – 45, 46, amalgam filling on vestibular face of 46; intense carbonization of the bone

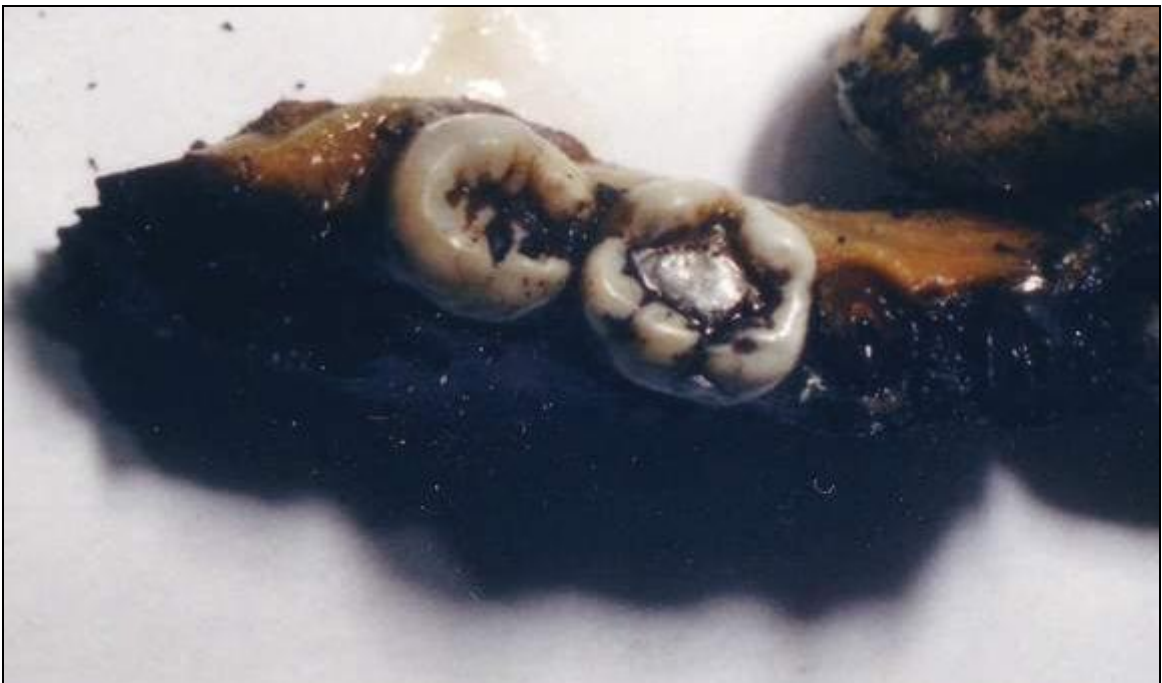

Photo 2 – right mandible fragment, – 45, 46, amalgam filling on occlusal face of 46; intense carbonization of the bone

We performed radiographs of the maxilla (photos 3 & 4), from different angles, that have confirmed the partial eruption of tooth 28.

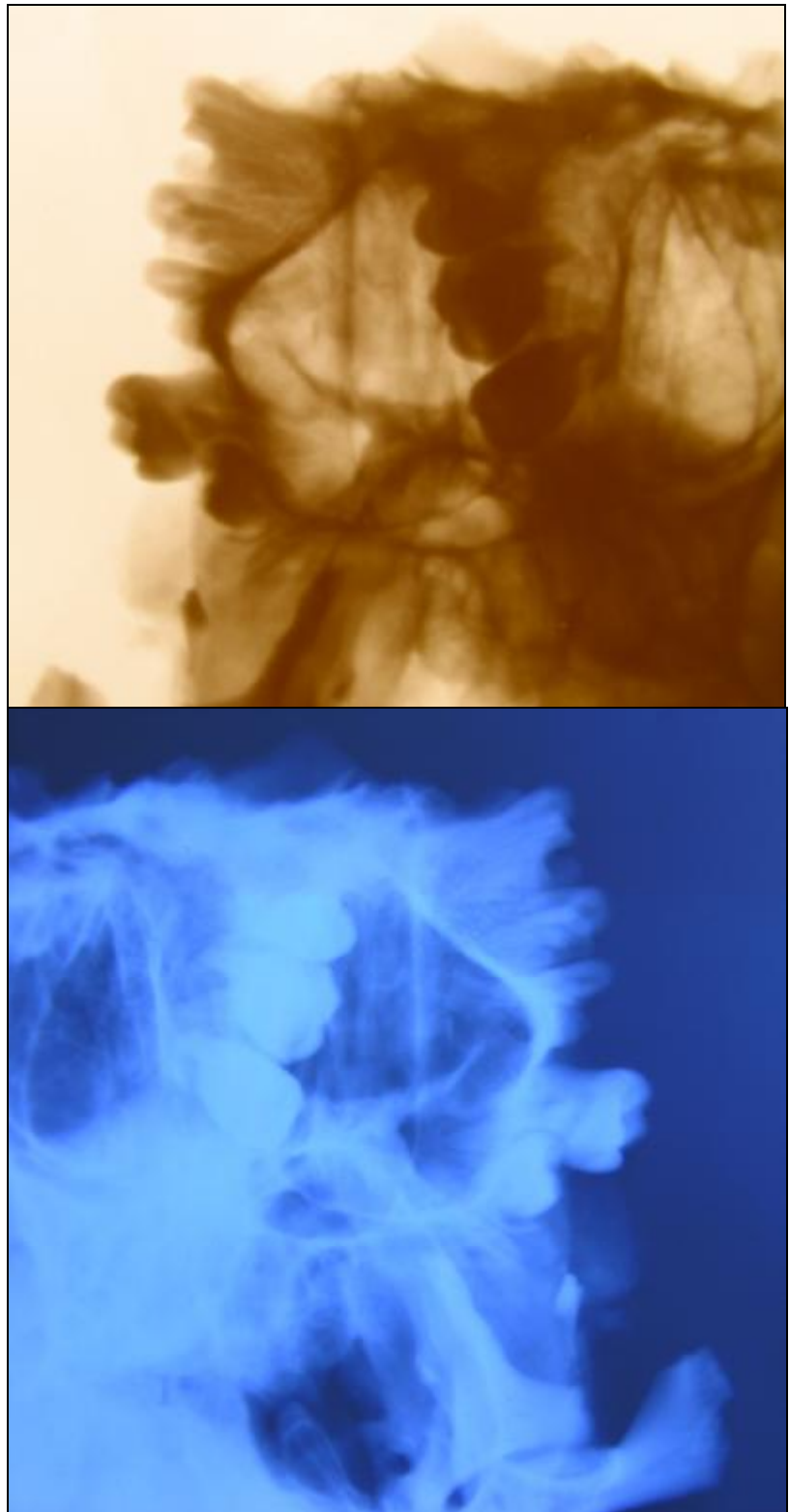
*The parts of the neck, thorax and scapular girdle* show traces of combustion:

- The soft tissues of the back are partially carbonized. This fragment has, attached, the following structures: left arm, elbow and the left humeral head.
- The cervical vertebrae, left clavicle and both scapulae have no visible alterations.
- The right clavicle, right ribs from 1 to 6 and left ribs from 1 to 8 are carbonized.
- The sternal manubrium is separated from the sternal body.
- Thoracic viscera are also carbonized. We found the heart and lungs, with black blood clots in its chambers. Lungs are black, both on surface and sections.

### **B. Fragments of the lower part of the body**

The material consists of parts of the abdomen, pelvis and the proximal ends of the thighs, that express the following features:

- The soft tissues of the lumbar region, the proximal ends of the thighs and the abdominal viscera –are carbonized.
- The pelvic face of the sacrum is slightly concave and the promontorium is prominent. Iliac fossa is slightly concave.



**Fig. 4** Photos 3 and 4: X-ray of the left mandible, from 2 incidences, showing partial eruption of 28

- The right hip bone has a vertically oriented iliac fossa, that is also very slightly concave.
- The fragment has attached the proximal ends of the thighs, that are carbonized.
- Genitalia are partially carbonized. We have performed incisions that allowed us to identify the testicles that are grey – reddish colored, both on surface and on sections.
- Liver is small, hard, brownish/grey on sections and covered with ashes on the surface.
- Spleen is small, black colored on sections.
- The left kidney, pancreas and transverse colon are forming a visceral block, both kidneys are black/reddish colored.

Carbonized fragments of both shanks and a foot fragment – had all bones conglutinated, forming a compact mass, proof of prolonged action of very high temperatures. A fragment of burned sock is attached to the distal end.

### C. Dispersed bony fragments

The bony fragments consisted of: one distal epiphysis of the right tibia, a fragment of the proximal epiphysis of tibia and one of the distal epiphysis of femur, both talus bones, a foot fragment, 18 diaphysis fragments (their dimensions and morphology cannot allow identification of bones that they belong to), a fragment of right humerus distal epiphysis, a proximal ulna fragment (that accurately fits to the previous fragment), a distal fragment of ulna diaphysis, 10 rib fragments and 8 fragments belonging to the skull vault.

The jeans fragments covering parts of the body have been analysed in the police forensic laboratory.

### Laboratory examinations:

*Toxicological analysis* on body fragments could not determine either the presence / absence of carboxi-hemoglobin or its concentration, due to the very high degree of tissues' degradation.

*Serological analysis* performed on soft tissue fragments established that the remains belonged to blood group 0. Absorption-elution method was used and H antigen was identified. We considered the result as non-concluding, false positive, due to degradation of the proteic markers.

*DNA analysis* compared profiles of the DNA extracted from the carbonized remains with those of the DNA from the missing person's (E.D.) parents. The probability of positive identification was of 99.999999928%

### Conclusions of the expertise

1. There have been established the identity of the person to which the human carbonized remains belong:

- male person – gender has been determined by anthropological examination of the sacrum and the right coxal bone and by identification of male genitalia
- age of the person could not have been accurately estimated, due to the high degree of carbonization of all available bone fragments, that were extremely fragile. Though, the abrasion degree of the teeth indicates an age range of 25 – 30 years old.

- Blood group, determined as 0, could not be considered as a positive result, due to the destruction of the blood group proteic markers by prolonged exposure to high temperature.
- The odontological examination (including radiographs) established the correspondence between the features of the teeth found among the remains (28, 38, 46) and those mentioned on the dental records presented by the police.
- DNA analysis established a 99.999999928% probability of coincidence between the DNA profile extracted from the carbonized remains and DNA profiles of the missing person's parents.

2. The high degree of body's carbonization did not allow to determine the presence of any kind of traumatic injuries on the examined pieces, produced either by assault or by a car crash. Due to this fact, we had no objective data to lead us to a possible cause of death.

Victim's identification has been accomplished by comparing the results of anthropological, odontological and DNA examination with the data provided by police.

## References

1. Hillson E., *Dental Anthropology*, Cambridge University Press, 2003
2. Klepinger L.L., *Fundamentals of Forensic Anthropology (Advances in Human Biology)* John Wiley & Sons Inc., 2006
3. Krogman W., Iscan M.Y., *Human Skeleton in Forensic Medicine*, C.C. Thomas; 2nd edition, 1986
4. Pellico L.G., Camacho F.J.F., Biometry of the anterior border of the human hip bone: normal values and their use in sex determination, *J Anat.* 1992 December; 181(Pt 3): 417–422
5. Rathbun T.A., Buikstra J.E., *Human Identification: Case Studies in Forensic Anthropology*, C. C. Thomas, 1984
6. Wittwer-Backofen U., Gampe J., Vaupel J.W., Tooth cementum annulation for age estimation: Results from a large known-age validation study, *Am.J. Phys. Anthr.*, vol. 123, issue 2, febr. 2004 (p 119-129)

---

<sup>i</sup> Authors note: The case has been presented as poster at the 17<sup>th</sup> Meeting of the International Academy of forensic Sciences, Hong Kong, August 2005.